Neuroimaging Correlates of Parent Reported Executive Dysfunction Following Pediatric Traumatic Brain Injury or Orthopedic Injury: A Preliminary Investigation

Adam T. Schmidt, Ph.D., Elisabeth A. Wilde, Ph.D., Kimberley D. Orsten, M.Sc., Xiaoqi Li, M.S., & Harvey S. Levin, Ph.D.

Baylor College of Medicine

PM&R Physical Medicine & Rehabilitation

INTRODUCTION

Traumatic brain injury (TBI) is a significant cause of mortality and morbidity in young children and adolescents [1].

In addition to various cognitive, behavioral, and social deficits, children who sustain a TBI frequently exhibit significant executive dysfunction [2].

Studies demonstrate executive deficits on standard laboratory measures [2, 3], as well as on more "ecologically valid" parent measures of executive functioning [4-6].

Additionally, TBI often results in volume loss in various brain regions especially frontal lobes, subcortical areas such as the basal ganglia and hippocampus, and major fiber bundles such as the corpus callosum and anterior commissure [7-12].

Previous studies demonstrate that parent reported executive abilities as measured by scores on the Behavior Rating Inventory of Executive Function (BRIEF) are related to frontal brain volumes in typically developing children [13].

The aim of the current study was to examine the relationship between gray and white matter volumes in various frontal lobe regions acquired at 3 months post-injury (PI) with parent reported scores on the BRIEF 3 months and 1 year following pediatric TBI or orthopedic injury (OI).

TBI

- N = 40
- Moderate to severe TBI = Glasgow Coma Scale (GCS)[14] scores of 9 to 12 OR GCS scores of 13 to 15 with brain lesions indicated by CT scans.
- Severe TBI = GCS scores of 3 to 8.
- English speaking
- No previous hospitalization for head injury or diagnosis of a developmental disability

OI

- N = 43
- Mild to moderate orthopedic injuries as defined by the Abbreviated Injury Scale [15].
- English-speaking
- No previous hospitalization for head injury or diagnosis of a developmental disability.

Behavior Rating Inventory of Executive Function (BRIEF) [4]

- The BRIEF is a parent report measure that assesses behavioral manifestations of executive functioning. It yields a broad measure of overall executive abilities (i.e., General Executive Composite [GEC]) and two more focused index scores (the Metacognitive Index [MI] and the Behavior Regulation Index [BRI]). Internal consistency coefficients range from 0.80 to 0.98. Mean test-retest reliability across the individual scales is 0.81.

MRI Acquisition:

T1-weighted 3D sagittal acquisition series were performed on Philips Intera 1.5T whole body scanners (Philips, Cleveland, OH).

Parameters included 1.0-mm-thick slices; 0mm slice gaps; TE=4.6ms/TR=15ms; FOV=256/RFOV=100%; Reconstructed voxel size M/P/S (mm)=1.0/1.0/1.0.

MRI Post-processing:

Cortical reconstruction and volumetric segmentation were performed with the FreeSurfer image analysis suite [16].

Results for each subject were visually inspected using the FreeSurfer toolkit at multiple points in the analysis stream to ensure accuracy of registration, skull stripping, segmentation, and cortical surface reconstruction. Manual editing was performed to optimize accuracy.

To reduce the number of analyses and to highlight brain regions relevant to the Aims, we combined volumes of cortical subregions generated by FreeSurfer to create cortical composite areas including 1) total frontal, 2) dorsolateral frontal, 3) orbitofrontal, 4) cingulate 5) corpus callosum. These composite areas are shown in Figure 1.

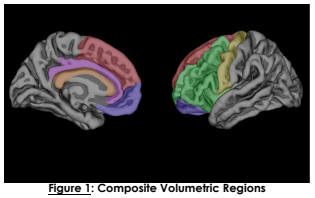

Figure 1: Composite Volumetric Regions

Total Frontal
Orbital Frontal
Dorsolateral Prefrontal
Cingulate
Corpus Callosum

RESULTS

Total Gray Matter Volume in the Cingulate

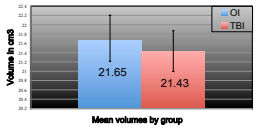

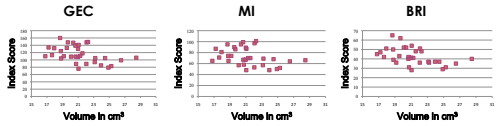

The relationship of total cingulate gray matter volume at 3 months PI to BRIEF indices scores at 12 months PI for the **TBI group.**

Total Frontal Gray Matter Volume

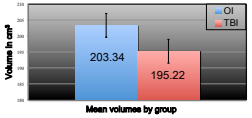

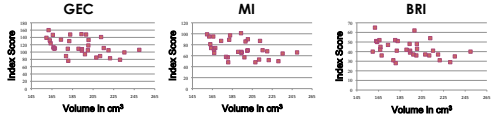

The relationship of total frontal gray matter volume at 3 months PI to BRIEF indices scores at 12 months PI for the **TBI group.**

Left DLPFC Gray Matter Volume

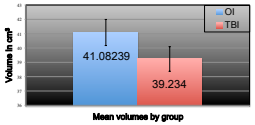

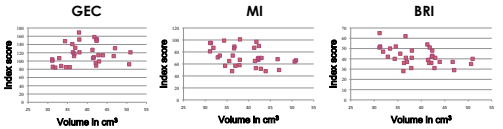

The relationship of left DLPFC gray matter volume at 3 months PI to BRIEF indices scores at 12 months PI for the **TBI group.**

DISCUSSION

Results indicate that children with TBI demonstrated widespread differences in frontal volumes 3 months PI (when controlling for age). Some of the most striking differences included total frontal gray matter, left DLPFC gray matter, and total cingulate gray matter.

Moreover, these data indicate significant differences in BRIEF index scores between groups at 3 months PI ; however, these differences dissipated at 12 months PI – a pattern indicative of behavioral recovery within the TBI group.

When examining the relationship between brain volumes 3 months PI and BRIEF index scores at the same time point (data not shown in result section above), no significant relations existed for either group. Conversely, within the TBI group, brain volumes at 3 months PI were significantly negatively related to BRIEF index scores 12 months PI.

Although we observed a number of significant correlations, gray matter volume of the left DLPFC in particular was strongly negatively related to all three BRIEF index scores (i.e., lower DLPFC volumes indicated more problems on the BRIEF) in the TBI group only. Similarly, BRIEF BRI demonstrated a relatively stronger relationship with brain volumes than either MI or GEC.

It is curious that we did not find many differences in terms of white matter volume and/or relationship of white matter to BRIEF scores. It is possible that another technique such as DTI would have been more sensitive to white matter differences following TBI. Further, developmental level and mechanism of injury may both contribute to the impact of TBI on white matter integrity thus obscuring the current findings.

It is also notable that we did not find significant relationships between BRIEF scores and brain volumes at 3 months while relationships emerged at 12 months PI. This, pattern in conjunction with the lack of significance between groups in BRIEF index scores at 12 months suggests that volumetric measures at 3 months PI may be indicative of cognitive or brain reserve within the TBI group. That is, individuals with greater volumes in certain frontal regions at 3 months PI may be at decreased risk for long-term behavioral sequela.

Obviously, this explanation is speculative and would be strengthened by longer-term follow-up both with behavioral and imaging measures as well as with other imaging analyses (e.g., lesion analysis).

REFERENCES

1 Langlois, J. A., Kegler, S. R., Butler, J. A., Gotsch, K. E., Johnson, R. L., Reichard, A. A., Webb, K. W., Coronado, V. G., Selassie, A. W. and Thurman, D. J. (2003). Traumatic brain injury-related hospital discharges. Results from a 14-state surveillance system, 1997.MMWR Surveill Summ, 52(4), 1-20.
2 Levin, H. S. and Hanten, G. (2005). Executive functions after traumatic brain injury in children.Pediatr Neurol, 33(2), 79-93.
3 Slomine, B. S., Gerring, J. P., Grados, M. A., Vasa, R., Brady, K. D., Christensen, J. R. and Denckla, M. B. (2002). Performance on measures of executive function following pediatric traumatic brain injury.Brain Inj, 16(9), 759-772.
4 Gioia, G. A., Isquith, P. K., Guy, S. C. and Kenworthy, L. (2000). Behavior Rating Inventory of Executive Function.Journal(Issue).
5 Soeno, H. W., Slomine, B. S., Dreer, L. E., Suskauer, S. J., Grados, M. A., Gerring, J. P., Christensen, J. R., Denckla, M. B. and Levin, H. S. (2004). Executive functioning in the first year after pediatric traumatic brain injury.Pediatrics, 114(1), e86-95.
6 Vriezen, E. R. and Pigott, S. E. (2002). The relationship between parental report on the BRIEF and performance-based measures of executive function in children with moderate to severe traumatic brain injury.Neuropsychol Dev Cogn Sect D Clin Neuropsychol, 23(4), 179-204.
7 Gale, S. D., Baxter, L., Roundy, N. and Johnson, S. C. (2005). Traumatic brain injury and grey matter concentration: a preliminary voxel based morphometry study.J Neurol Neurosurg Psychiatry, 76(7), 984-988.
8 Ghosh, A., Wilde, E. A., Hunter, J. V., Bigler, E. D., Chu, Z., Li, X., Vasquez, A. C., Morales, D., Vallampalli, R. and Levin, H. S. (2009). The relation between Glasgow Coma Scale score and later cerebral atrophy in paediatric traumatic brain injury.Brain Injury, 23(3), 228-233.
9 Yeger, K., Jangaz, C., Levin, H. S., Jurado, M. A., Perez-Gomez, M., Barroso-Paz, D., Barrios, M., Alvarez, A., Bartumeus, F. and Muruzabe, J. M. (2001). Correlation of atrophy measures on MRI with neuropsychological sequelae in children and adolescents with traumatic brain injury.Brain Inj, 15(3), 211-225.
10 Wilde, E. A., Bigler, E. D., Pedroza, C. and Hyzer, D. K. (2006). Post-traumatic amnesia predicts long-term cerebral atrophy in traumatic brain injury.Brain Inj, 20(7), 695-699.
11 Wilde, E. A., Bigler, E. D., Hunter, J. V., Fearing, M. A., Hanten, G., Newsome, M. R., Scheibel, R. S., Li, X. and Levin, H. S. (2008). Diffusion tensor imaging in the corpus callosum in children after moderate to severe traumatic brain injury.J Neurotrauma, 25 (11), 1412-1426.
12 Wilde, E. A., Bigler, E. D., Hunter, J. V., Fearing, M. A., Scheibel, R. S., Newsome, M. R., Johnson, J. L., Buchsbaum, J., Li, X. and Levin, H. S. (2007). Hippocampus, amygdala, and basal ganglia morphometrics in children after moderate-to-severe traumatic brain injury.Dev Med Child Neurol, 49(4), 294-299.
13 Mahone, M. E., Martin, R., Kates, W. R., Hay, T. and Horska, A. (2009). Neuroimaging correlates of parent ratings of working memory in typically developing children.Journal of the International Neuropsychological Society, 15, 31-41.
14 Teasdale, G. and Jennett, B. (1974). Assessment of coma and impaired consciousness. A practical scale.Lancet, 2(7872), 81-84.
15 Copes, W. S., Lawnick, M., Champion, H. R. and Sacco, W. J. (1988). A comparison of Abbreviated Injury Scale 1980 and 1985 Journal of Trauma, 28, 78-84.
16 Athinoula A. Martinos Center for Biomedical Imaging. (2005). Freesurfer.